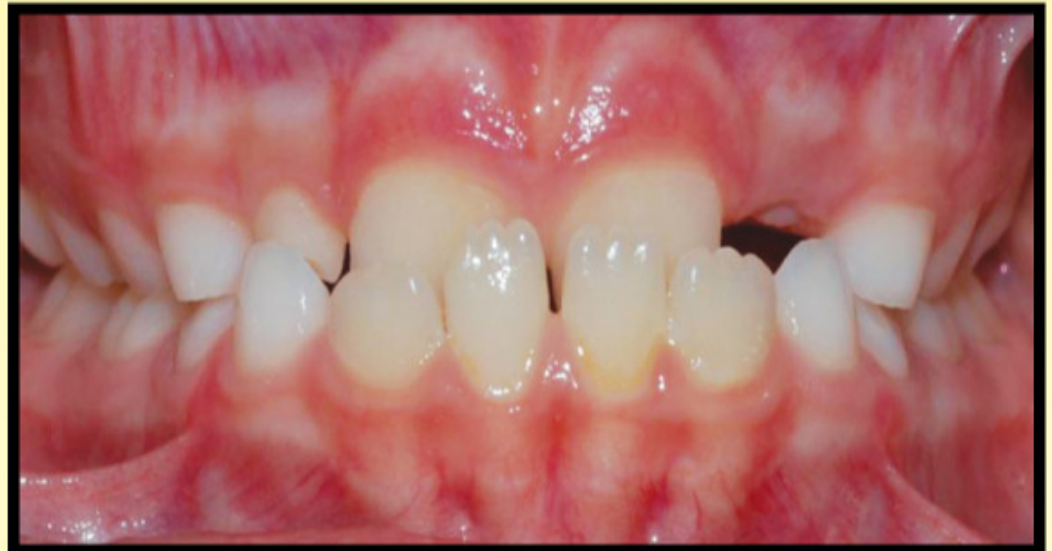



Oral Health Division
Ministry of Health Malaysia

**MANAGEMENT OF ANTERIOR
CROSSBITE IN THE
MIXED DENTITION**



2nd Edition
June 2013

MOH/P/PAK/265.13(GU)



Oral Health Division
Ministry of Health Malaysia

MANAGEMENT OF ANTERIOR CROSSBITE IN THE MIXED DENTITION

2nd Edition

June 2013

STATEMENT OF INTENT

The following guidelines update and supplant the original guidelines developed in 2002 and is based on the best available contemporary evidence. It is intended as a guide for the best clinical practice in the management of anterior crossbite in children. However, it must be noted that adherence to this guidelines does not necessarily lead to the best clinical outcome in individual patient care. Every healthcare provider is responsible for the management of their patient based on the clinical presentation and management options.

REVIEW OF THE GUIDELINES

The guidelines had been issued in 2013 and will be reviewed in 2017 or earlier if new evidence becomes available.

CPG Secretariat
Dental Technology Section
Oral Health Division
Level 5, Block E10, Parcel E
Government Offices Complex
62590 Putrajaya, Malaysia

Electronic version available on the following websites:

<http://www.moh.gov.my>

<http://www.ohd.gov.my>

<http://www.acadmed.org.my>

	TABLE OF CONTENTS	PAGE
	GUIDELINES DEVELOPMENT	iv-v
	OBJECTIVE, SPECIFIC OBJECTIVES, CLINICAL QUESTIONS,	vi
	TARGET POPULATION, TARGET USER, HEALTHCARE SETTINGS ORGANISATIONAL BARRIERS AND COST IMPLICATIONS	vii
	PROPOSED CLINICAL AUDIT INDICATORS FOR QUALITY MANAGEMENT	viii
	LEVELS OF EVIDENCE AND GRADES OF RECOMMENDATIONS	ix
	MEMBERS OF THE GUIDELINES DEVELOPMENT GROUP	x-xi
	MEMBERS OF THE REVIEW COMMITTEE	xii-xiii
1	INTRODUCTION	1
2	TYPES OF ANTERIOR CROSSBITE	1
	2.1 Dental crossbite	1
	2.2 Functional crossbite	2
	2.3 Skeletal crossbite	3
3	AETIOLOGY	4
	3.1 Skeletal	4
	3.2 Dental	5
	3.3 Local factors	5
	3.4 Pathological conditions	5-6
4	EARLY INTERVENTION	7
5	CONTRAINDICATIONS	8
6	EXAMINATION	9
	6.1 Patient assessment	9
	6.2 History	9
	6.3 Extra-oral examination	9
	6.4 Intra-oral examination	10
	6.5 Radiographic examination	10
	6.6 Study models	11
	6.7 Clinical photographs	11-12

7	DIAGNOSIS	13-14
8	TREATMENT	15
	8.1 Treatment principles	15
	8.2 Factors to consider prior to selection of treatment modalities	16
	8.3 Upper removable appliance	16-17
9	DESIGNING REMOVABLE APPLIANCE	18
	9.1 General Principle	18
	9.2 Active Components	18
	9.3 Retentive Components	19-20
	9.4 Anchorage	20
	9.5 Baseplate	21
10	MANAGEMENT OF REMOVABLE APPLIANCE	21
	10.1 Fitting Removable Appliance	21
	10.2 Review Appointments	22-24
11	FIXED APPLIANCE	25
12	INCLINED BITE PLANE	25
13	FUNCTIONAL APPLIANCE	26
14	FACE MASK/ PROTRACTION HEADGEAR	26
15	CHIN CUP OR CHIN CAP	27
	REFERENCES	28-32
	APPENDIX 1	33
	APPENDIX 2	34
	ALGORITHM FOR MANAGEMENT OF ANTERIOR CROSSBITE IN THE MIXED DENTITION	35
	ACKNOWLEDGEMENTS, DISCLOSURE STATEMENT, SOURCES OF FUNDING	36

GUIDELINES DEVELOPMENT

The Development Group for this Clinical Practice Guidelines (CPG) consisted of Orthodontic Specialists, Dental Paediatric Specialists, Dental Public Health Specialists and Dental Officers. The review committee was actively involved in the development process of the guidelines.

The previous edition of the CPG on Management of Anterior Crossbite in the Mixed Dentition (2002) was used as the basis for the development of the current guidelines.

Several improvements have been introduced in this edition. In addition to the general text and photographic updates, new and updated information has been included. Clinical audit indicators have also been identified for the purpose of monitoring and evaluating outcomes.

Evidence was retrieved from publications from the year 2002 onwards. Literature search was carried out using the following electronic databases: PUBMED/MEDLINE; Cochrane Database of Systemic Reviews (CDSR); ISI Web of Knowledge; and full text journal articles via OVID search engine. In addition, the reference lists of all relevant articles retrieved were searched to identify further studies. The search process was conducted between May 2012 and May 2013 and only literature in English was included.

Articles retrieved were appraised by at least two members, and graded according to the levels of evidence presented in the form of evidence tables and discussed during group meetings. The levels of evidence was adopted from the modified version of the United States (U.S) / Canadian Preventive Services Task Force, while the grading of recommendations was based on the modified version of the Scottish Intercollegiate Guidelines Network (SIGN). The CPG was based on the findings of relevant published evidence.

Ideally, the patients' views and preferences need to be considered in the development of CPGs. However, it was not feasible at present for this CPG. Nevertheless, patient information leaflets will be developed in the future to facilitate the dissemination of relevant and important information to the public on anterior crossbite in the mixed dentition.

The draft was reviewed by a team of internal / external reviewers and made available on the websites of the Ministry of Health, Malaysia and Academy of Medicine, Malaysia for comments and feedback. Recommendations were presented to the Technical Advisory Committee for CPGs, and finally to the Health Technology Assessment and CPG Council, Ministry of Health, Malaysia for approval.

OBJECTIVE

To provide evidence-based guidance in the management of anterior crossbite in the mixed dentition.

SPECIFIC OBJECTIVES

- i. To disseminate and reinforce knowledge on the management of anterior crossbite among dental healthcare professionals
- ii. To provide timely and appropriate management of anterior crossbite by dental healthcare professionals

CLINICAL QUESTIONS

The clinical questions addressed by the guidelines are:

- i. How to recognize and diagnose the different types of anterior crossbite?
- ii. What are the types of crossbite that can be treated successfully by early intervention?
- iii. What is the importance of timely intervention of anterior crossbite in children?
- iv. How can early treatment of anterior crossbite in children be managed successfully?

TARGET POPULATION

The primary target group is children in mixed dentition with dental or functional crossbite which affects one or more permanent teeth.

i. Inclusion criteria

- Children with anterior crossbite of dental origin and functional crossbite.

ii. Exclusion criteria

- Children with anterior crossbite associated with skeletal discrepancies.

TARGET USER

The guideline is applicable to dental healthcare providers involved in the management of anterior crossbite in children.

HEALTHCARE SETTINGS

All dental departments and clinics are the common areas of use.

ORGANISATIONAL BARRIERS AND COST IMPLICATIONS

One of the major responsibilities of dental healthcare providers is to intercept a developing malocclusion in children. Anterior crossbite is often observed in the mixed dentition and there is a universal agreement that the condition should be treated early. Some general dental practitioners are unfamiliar with treating anterior crossbite in children.

Delaying such interceptive treatment may worsen the malocclusion, is detrimental to dental health and may cause functional problems. In some instances, it may lead to unfavourable jaw growth. Success in treatment is mostly dependent on the timely and appropriate management of the anterior crossbite. Hence, it is important to disseminate the knowledge among healthcare providers, as well as to lay people, to actively seek treatment as an interceptive measure. This can be facilitated through the development of appropriate training modules, quick references and patient information leaflets.

Cost implications on management of anterior crossbite in children may vary depending on several factors, such as patient's age and cooperation, operator's experience and appliances used. Successful treatment and stability following correction would depend on adequate overbite, a good interincisal angle and favourable growth.

PROPOSED CLINICAL AUDIT INDICATORS FOR QUALITY MANAGEMENT

$$\text{Success rate of anterior crossbite treatment} = \frac{\text{Number of anterior crossbite cases treated successfully}}{\text{Total number of anterior crossbite cases treated}} \times 100$$

(*successful treatment is defined as correction of anterior crossbite within 9 months)

LEVELS OF EVIDENCE AND GRADES OF RECOMMENDATIONS

LEVEL	STUDY DESIGN
I	Evidence obtained from at least one properly designed randomised controlled trial
II-1	Evidence obtained from well-designed controlled trials without randomization
II-2	Evidence obtained from well-designed cohort or case-control analytic studies, preferably from more than one centre or research group
II-3	Evidence obtained from multiple time series with or without the intervention. Dramatic results in uncontrolled experiments (such as the results of the introduction of penicillin treatment in the 1940s) could also be regarded as this type of evidence
III	Opinions or respected authorities, based on clinical experience; descriptive studies and case reports; or reports of expert committees

Source: Adapted from U.S./Canadian Preventive Services Task Force

GRADES OF RECOMMENDATION

A	At least one meta analysis, systematic review or RCT or evidence rated as good or directly applicable to the target population
B	Evidence from well conducted clinical trials, directly applicable to the target population and demonstrating overall consistency of results; or evidence extrapolated from meta analysis, systematic reviews or RCT
C	Evidence from expert committee reports, or opinions and or clinical experiences of respected authorities; indicates absence of directly applicable clinical studies of good quality

Source: Modified from the Scottish Intercollegiate Guidelines Network (SIGN)

MEMBERS OF THE GUIDELINES DEVELOPMENT GROUP

Chairperson	Secretary
Dr. Ruslan bin Sulaiman Senior Consultant Orthodontist Klinik Pergigian Sg Chua Selangor	Dr. Rozaimah bt. Mat Shafiei Orthodontist Klinik Pergigian Taiping Taiping, Perak
Members (alphabetical order)	
Dr. Asma Ashari Dental Officer Klinik Pergigian Tanjong Karang Selangor	Dr. Nik Fatimah Nik Fauzi Dental Officer Klinik Pergigian Selayang Baru Batu Caves, Selangor
Dr. Evelyn Lee Gaik Lyn Orthodontist Klinik Pergigian Cahaya Suria Jalan Tun Perak, Kuala Lumpur	Datin Dr. Nooral Zeila bt Junid Dental Public Health Specialist Oral Health Division Ministry of Health Malaysia
Dr. Lillybia@Emily Ebin Orthodontist Klinik Pergigian Sandakan Sandakan, Sabah	Dr. Ong Siang Ching Orthodontist Klinik Pergigian Pasir Puteh Pasir Puteh, Kelantan
Dr. Lim Lay Yong Orthodontist Klinik Pergigian Bandar Botanic Klang, Selangor	Dr. Saravanan a/l Alagu Orthodontist Hospital Queen Elizabeth II Kota Kinabalu, Sabah
Lt Kol (Dr) Mumtaj Nisah Abd Rahim Orthodontist Armed Forces Dental Centre Ministry of Defence Kuala Lumpur	Dr. Tan Ying Ying Orthodontist Klinik Pergigian Mak Mandin Butterworth, Pulau Pinang

<p>Dr. Murshida Marizan Nor Orthodontist and Lecturer Orthodontic Department Faculty of Dentistry Universiti Kebangsaan Malaysia(UKM) Kuala Lumpur</p>	<p>Dr. Yeoh Chiew Kit Orthodontist Klinik Pergigian Pakar Ortodontik Teluk Wanjah Alor Setar, Kedah</p>
<p>Dr. Nazatul Sabariah Ahmad Paediatric Dental Specialist and Lecturer Faculty of Dentistry Universiti Sains Islam Malaysia (USIM) Pandan Indah, Kuala Lumpur</p>	<p>Dr. Zainab Shamdol Dental Public Health Specialist Oral Health Division Ministry of Health Malaysia</p>
<p>Dr Azizah Mat Dental Public Health Specialist Oral Health Division Ministry of Health Malaysia</p>	<p>Zabidah bt Othman Dental Nurse Oral Health Division Ministry of Health Malaysia</p>

MEMBERS OF THE REVIEW COMMITTEE

The guideline was reviewed by a panel of independent reviewers from both local and international experts. They were asked to comment primarily on the comprehensiveness and accuracy of interpretation of the evidence supporting the recommendations in the guideline.

Internal reviewers

Dr Rashidah bt Dato' Burhanuddin
Senior Consultant Orthodontist,
Head of Orthodontic Specialty,
Kuala Lumpur
Wilayah Persekutuan

Dr Bahruddin bin Saripudin
Paediatric Dental Specialist
Serdang Hospital
Selangor

Dr Khairil Aznan Mohd Khan
Head of Orthodontic Department
Faculty of Dentistry
Universiti Kebangsaan Malaysia
Kuala Lumpur

The following external reviewers provided comments and feedback on the proposed draft.

External reviewers

Major General Dato' Dr Sukri bin Hussin
Director of Dental Services
Malaysian Armed Forces
Ministry of Defence Malaysia
Kuala Lumpur

Prof Dato' Dr Wan Mohamad Nasir bin Wan Othman
Foundation Dean
Faculty of Dentistry
Universiti Sains Islam Malaysia

Dr Ama Johal
Senior Clinical Lecturer/Consultant Orthodontist
Bart's & The London Queen Mary School of Medicine & Dentistry

Prof Ferranti Wong
Professor / Honorary Consultant and Head of Paediatric Dentistry
Department
Bart's & The London Queen Mary School of Medicine & Dentistry

1. INTRODUCTION

Anterior crossbite occurs when the upper anterior teeth occlude lingual to the lower anterior teeth. This may involve one or more anterior teeth either in the deciduous or permanent dentition. There is a presence of an abnormal relationship of a tooth or teeth to the opposing teeth, in which normal labiolingual relationship is reversed.

Prevalence of anterior crossbite varies significantly from one ethnic group to another. According to Lin JJ,^{1,level III} the prevalence of anterior crossbite was 13.83% in a Taiwanese sample of 7,090 elementary and junior high school students, aged 9 to 15 years old.

2. TYPES OF ANTERIOR CROSSBITE

There are three types of anterior crossbite:

2.1 Dental crossbite

Patients presented with Class I skeletal relationship (straight facial profile in centric occlusion) with one or more teeth in crossbite. ([Figure 1](#)).

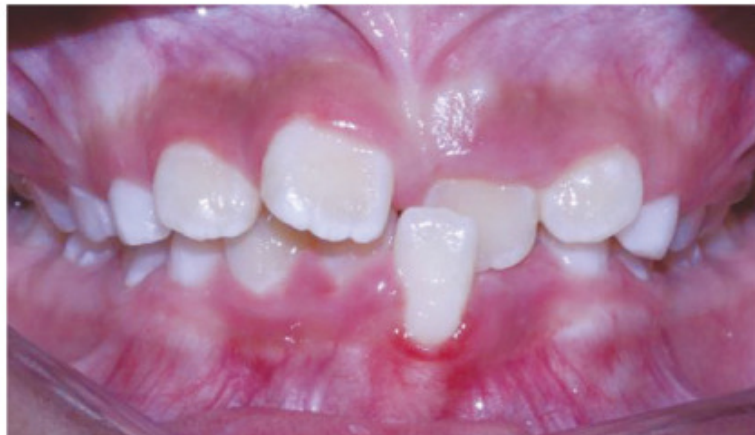

Figure 1. Dental crossbite.

2.2 Functional crossbite (Pseudo Class III)

Functional crossbite is a positional malrelationship with an acquired neuro-muscular reflex.^{2,level III} The malocclusion is caused by an occlusal interference that leads to mandibular displacement either anteriorly or laterally in order to achieve maximum intercuspation. The incidence is 2-3%, which is one and a half times that of skeletal Class III malocclusion in the same Chinese population.^{3,level II-3}

Diagnostic characteristics of pseudo Class III:

- Majority showed no family history.
- Class I molar and canine relationships at centric occlusion and Class II or end to end relationship at centric relation (mandibular displacement).
- Decreased midface length.
- Forward position of the mandible with normal mandibular length.
- Retroclined upper incisors.
- Average inclination of lower incisors.^{4,level III}

2.3 Skeletal crossbite

This is a malocclusion with maxillary posterior teeth occluding lingual to the mandibular counterparts due to the discrepancy of the underlying skeletal relationship ([Figure 2](#)). Early treatment may not be successful due to the unpredictability of the growth pattern; hence referral to a specialist for management is necessary.

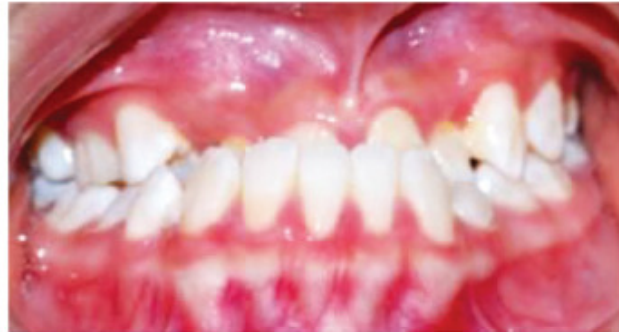
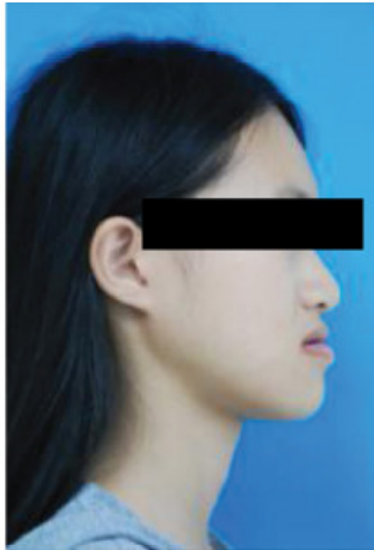
Figure 2. Skeletal crossbite.

3. AETIOLOGY

The possible causes of anterior crossbite include: -

3.1 Skeletal^{5-7,level III}

- Anterior posterior skeletal discrepancy is one of the main causes of anterior crossbites.
- It can be manifested as either a maxillary deficiency, mandibular excess or a combination of both usually associated with family history of Class III skeletal origin.

3.2 Dental^{5-7,level III}

- Crowding.^{8,level III}
- Occlusal interferences which result in mandibular displacement to achieve maximum intercuspation.

3.3 Local Factors^{5-7,level III}

- Palatal eruption path of maxillary incisors.
- Trauma to permanent teeth resulting in the incisors being displaced by luxation.
- Delayed shedding of deciduous teeth.
- Trauma to deciduous teeth resulting in displacement of deciduous or permanent tooth germs.

3.4 Pathological conditions^{5-7,level III}

- A cleft lip and palate patient may present with both anterior and posterior crossbites ([Figure 3](#)). Scar tissue of the cleft repair can restrain the growth of the maxilla, resulting in a narrow maxilla^{9,level II-2}
- Trauma or pathology of the temporomandibular joint can lead to restriction of the growth of mandible on one side leading to asymmetry.
- Arthritis, acromegaly, Duchenne's muscular dystrophy, condylar hyperplasia and osteochondroma.

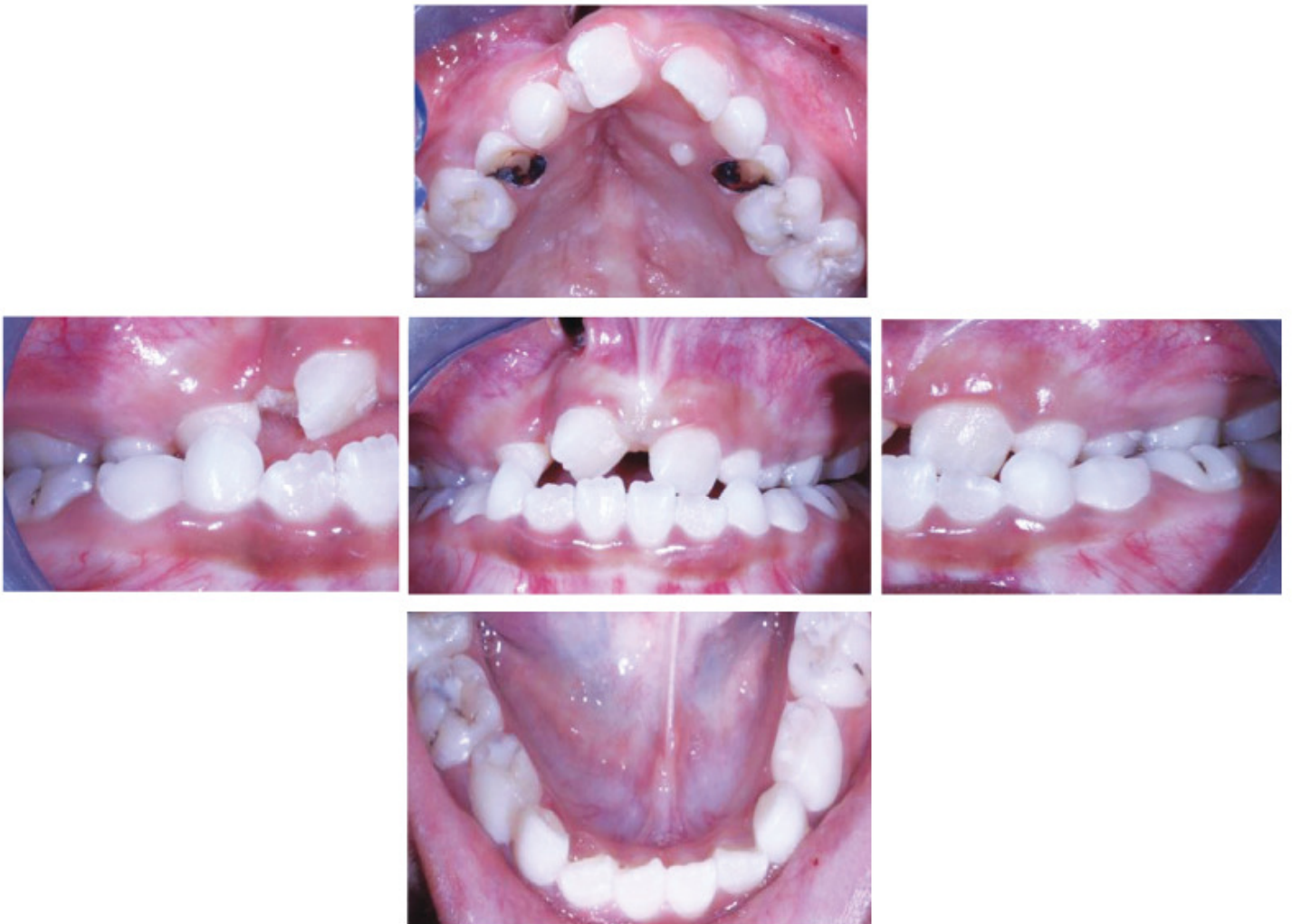

Figure 3. Anterior Crossbite in relation to Cleft Lip and Palate.

4. EARLY INTERVENTION

Early intervention is defined as orthodontic treatment before the definitive phase and should be limited to less than 9 months so that future compliance of the patient is not compromised.

Rationale for early intervention:

- Little possibility for self-correction.
- Crossbite in the primary dentition is believed to be transferred to the permanent dentition.^{10,level II-2;11,level III;12,level II-1;13,level III}
- Postponing treatment results in prolonged treatment of greater complexity.^{14,level III}
- Functional crossbite can develop from cuspal interference, resulting in a mandibular shift.
- Improve maxillary lip posture and facial appearance if corrected in the mixed dentition.^{15,level II-2}
- Provide space for eruption of canines. Lack of space in the arch could be caused by retroclined upper incisors.^{16,level II-2;17,level II}

If anterior crossbite is left untreated, it may lead to:

- Damage to the teeth in crossbite through attrition.^{16,level II-2}
- Gingival recession and loss of alveolar bone support to the lower incisors.^{16,level II-2}
- Mobility of the lower incisors affected by the crossbite.^{18,level III}

- Temporomandibular dysfunction, which has been associated with childhood anterior crossbite.^{16,level II-2;19,level III}
- Potential adverse growth influences on the mandible and the anterior portion on the maxilla,^{16,level II-2;20-22,level III} involving not just the teeth and alveolar processes, but also skeletal structures of the mandible and maxilla.^{23,level III}

RECOMMENDATION

Anterior functional crossbite should be treated early due to little possibility of self-correction and to prevent damage to oral structures.

(Grade C)

5. CONTRAINDICATIONS

- Patients who present with skeletal discrepancy, which may require joint orthodontic- surgical management.
- Where dento-alveolar compensation has taken place (proclined upper incisors, retroclined lower incisor).
- Minimal or no overbite.
- Non-compliant patient.

KEY MESSAGE

Patients with anterior crossbite of skeletal origin should be referred to an orthodontist for further management.

6. EXAMINATION

A thorough clinical examination and diagnosis of the anterior crossbite should be done to ascertain the aetiology of the crossbite.

6.1 Patient assessment

- Some of the common concerns regarding anterior crossbite are:
 - ◇ irregularity/ crowding of upper front teeth.
 - ◇ little/ no exposure of upper front teeth on smiling.
 - ◇ mobility of lower incisors.
 - ◇ gingival recession.
- Some patients may be unaware of their crossbite and have been referred by their general dental practitioner.

6.2 History

- Relevant medical / dental history should be noted.
- Family history of a Class III skeletal pattern.
- Social history.

6.3 Extra-oral examination

- Skeletal pattern: A-P, Vertical and Transverserelationships
- TMJ: tenderness, clicking, crepitus, mobility.
Any symptoms should be recorded.
- Soft tissue profile: straight, convex, concave.

6.4 Intra-oral examination

- General condition of the oral cavity should be assessed: oral hygiene, gingival health and DMF status.
- Assessment of the arches: crowding, spacing, inclination of incisors.
- Number of teeth involved in the anterior crossbite, overjet, overbite, buccal segment relationship and center line discrepancy.
- Signs of attrition and periodontal breakdown due to traumatic occlusion if present.
- Presence of mandibular displacement due to premature contact and the ability to achieve an edge-to-edge incisor relationship.

6.5 Radiographic examination

- OPG: To assess skeletal and dental tissues to detect any abnormalities. For dental tissue assessment, it is used to confirm the presence/absence of teeth, condition of teeth and the periodontal status; or
- Standard upper anterior occlusal: To detect any supernumerary teeth in the anterior region and if pathology is suspected in the anterior region.

6.6 Study models

- Study model and wax bite registration in maximum intercuspation must be taken for diagnosis and treatment planning. The study model may also be used for space analysis for the purpose of a detailed treatment planning.
- For medico-legal and research purposes.

6.7 Clinical photographs

Clinical photographs taken both extraorally and intraorally with standardized settings for pre and post-treatment records are advisable. An example of clinical photographs is shown in ([Figure 4a and 4b](#)).



Figure 4a. Extra oral photographs.

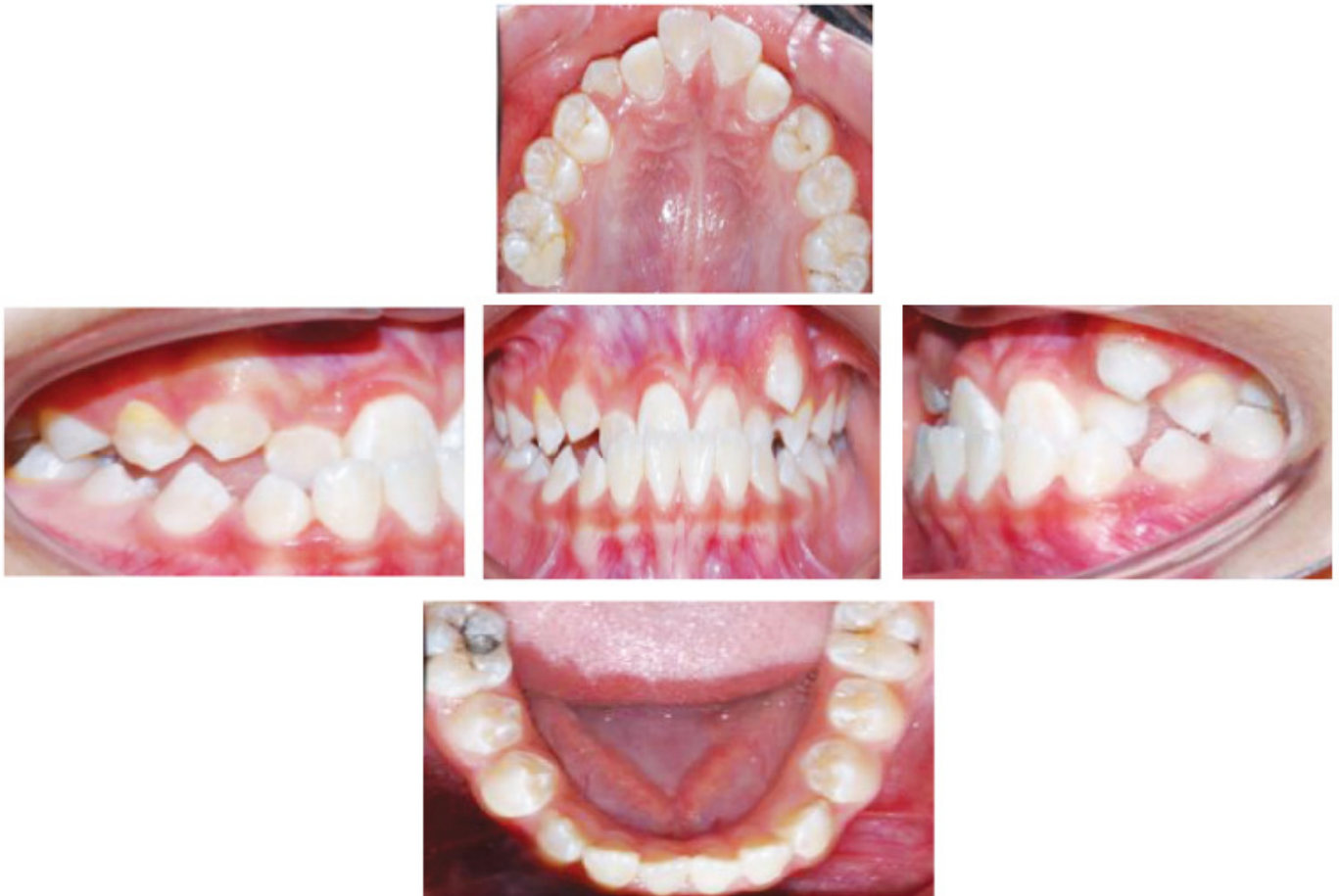

Figure 4b. Intra oral photographs.

RECOMMENDATION

Pretreatment diagnostic records

- Panoramic radiograph.
- Study casts.
- Photographs.

(Grade C)

7. DIAGNOSIS

- Correct diagnosis of the type of anterior crossbite is essential for successful treatment.
- In order to determine the cause of anterior crossbite, it is important to differentiate between skeletal or of dental origin.
- Dental crossbite can be managed early using simple orthodontic appliances.
- Functional and skeletal anterior crossbite require more complex treatment modalities and should be managed by Orthodontic Specialists.



Types of crossbite	Skeletal Anterior Crossbite	Dental Anterior Crossbite
Clinical presentation	 <p style="text-align: center;">Figure 5.</p>	 <p style="text-align: center;">Figure 6.</p>
Aetiology	<ul style="list-style-type: none"> ● Genetic or hereditary in most cases ● Maxilla and mandible size discrepancy 	<ul style="list-style-type: none"> ● Lack of space, crowding ● No maxilla and mandible size discrepancy
Maxillary incisors inclination	Proclined	Upright or retroclined
Mandibular incisors inclination	Retroclined	Proclined or upright
Anteroposterior discrepancy	Present	<ul style="list-style-type: none"> ● Not present ● If present can be associated with mandibular displacement (functional crossbite)
Transverse discrepancy	Can be associated with posterior crossbite	Not present If present can be associated with mandibular displacement (functional crossbite)
Mandibular growth pattern	Unfavourable growth patterns	Normal
Number of teeth in crossbite	Segments crossbite	One or more teeth

Table 1. Skeletal and Dental Anterior Crossbite Indicator. ^{9,level II-2;24,level II}

KEY MESSAGE

Role of general dental practitioners and dental nurses:

- Early detection.
- Interceptive treatment by GDP.
- Appropriate and timely referral to orthodontic specialists.

8. TREATMENT

8.1 TREATMENT PRINCIPLES

Anterior crossbite is corrected by:

- a. Dento-alveolar compensation i.e. proclination of upper teeth alone or combination of proclination of upper teeth and retroclination of lower teeth.
- b. Maxillary protrusion .
- c. Backward rotation of mandible.
- d. Combination of a,b & c (Surgery – Orthognathic).

8.2 FACTORS TO CONSIDER PRIOR TO SELECTION OF TREATMENT MODALITIES

- Adequate space in the arch to reposition the tooth.^{20,level III}
- Sufficient overbite to hold the tooth in position following correction.^{20,level III}
- Incisors inclination before treatment (An apical position of the tooth in crossbite that is the same as it would be in normal position.^{20,level III})
- A Class I occlusion.^{20,level III}
- Patient compliance.
- Timing of treatment.
- Periodontal breakdown.
- Growth potential.
- Level of operators knowledge and training.

8.3 UPPER REMOVABLE APPLIANCE

Upper removable appliances have been widely used in the treatment of anterior crossbite ([Figure 7](#)). Removable appliances act by applying tipping forces to the crowns of the teeth. Tooth movement occurs solely by tipping as only single-point contact is possible.

ADVANTAGES	DISADVANTAGES
Simple	Highly dependent on patient's compliance
Can be removed for oral hygiene purposes	Needs good laboratory support
Reduced chairside time	Only allows tipping movement.
Cost-effective	

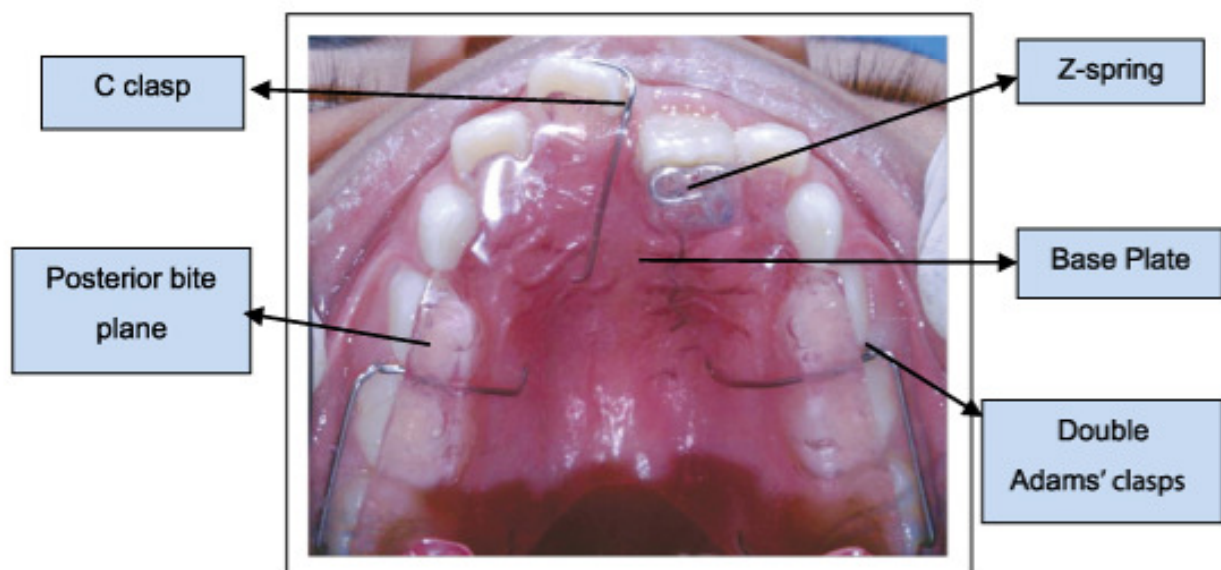


Figure 7. An example of a design of a URA

9. DESIGNING REMOVABLE APPLIANCE

9.1 General Principle

The success of removable appliance treatment depends on the design. The design should be simple for patients to use (Refer Appendix 1).

Components of Removable Appliances

- Active components.
- Retentive components.
- Anchorage.
- Baseplate.

9.2 Active Components

The active components provide force to move teeth. Examples of active components are springs, bows, expansion screw and elastics. The commonly used active components for anterior crossbite correction are Z- spring and expansion screw.

- **Z-springs**

A z-spring made of 0.5mm hard stainless steel wire is sufficient to correct a simple crossbite involving one tooth. The spring has an arm and two activation coils. The coils are of 3.0mm in diameter. The arm of the spring is placed on the palatal surface of the tooth.

Activation of spring is either by opening of the coils or pulling the outer arm of the spring forward and away from acrylic base plate. The recommended force is approximately 30g. The direction of activation is perpendicular to the tangent of the palatal surface of the tooth. This may need anterior retention as it may displace the appliance downward.

- **Expansion Screws**

Screws are used to procline two or more teeth. A screw applied large intermittent force to the teeth. It is placed parallel to the intended tooth movement. One of the advantages of the screw is a clasp can be placed on the teeth to be moved. It is very useful in cases where there is inadequate number of teeth for retention.

Screw is activated in the base plate by the patient at home according to the direction showed by the clinician. The activation is done one-quarter turn once weekly which separates the acrylic by about 0.25mm. More frequent adjustments, up to twice a week are possible but care must be taken not to overdo it as this can cause the appliance to be ill-fitting.

9.3 Retentive Components

Adequate retention is important for compliance and efficiency of the appliance. If the appliance is loose, the patient may have difficulty wearing it. Furthermore, the active components will not work effectively in a loose appliance. Common retentive components used are the Adams and Southend clasps.

- **Adams Clasp**

The clasp is commonly constructed on the first permanent molars using 0.7mm stainless steel wire. It can also be made on premolars using 0.6mm hard stainless steel wire.

The arrowhead is angled at 30° - 45° to engage the undercuts present at the junction of the mesial and distal surfaces of the buccal aspects of the tooth.

Clasps should be adjusted only when necessary. The clasps can be adjusted in two places, i.e. bend in the middle of the flyover and adjustment near the arrowhead.

- **Southend Clasp**

This clasp is preferred where incisors are to be used for retention. It is less obstructive and easily adaptable. The wire used for its construction is 0.7mm stainless steel. Retention is increased by bending the arrowhead towards the teeth.

9.4 Anchorage

Anchorage is a source of resistance to the reaction from the active components. Anchorage in removable appliance is provided by the baseplate and the retentive components.

9.5 Baseplate

The acrylic baseplate serves to hold together the other components of the appliance. A posterior bite plane should be incorporated to free the occlusion and allow the tooth in crossbite to move effectively. The posterior bite plane should be appropriate in thickness.

10. MANAGEMENT OF REMOVABLE APPLIANCE

10.1 Fitting Removable Appliance

- Before fitting the removable appliance in patient's mouth, ensure that it is the correct appliance for the patient and the design has been followed.
- Explain to the patient how the appliance works.
- Ensure there is no roughness on the fitting surface.
- Try in the appliance and adjust the active and retentive components where necessary.
- Demonstrate to the patient how to insert and remove the appliance and get the patient to practice doing it.
- Give clear instructions to the patient and parents/guardian, stressing on the importance of full time wear (refer Appendix 2).
- Arrange for review appointments.

10.2 Review appointments

- Ideally patients wearing removable appliance should be seen every 4-6 weeks.
- During the review appointment, the most important thing is to assess the patient's compliance. The clues for lack of compliance include:
 - ◇ Patient's lisp.^{25,level III}
 - ◇ Pooling of saliva.
 - ◇ The appliances look very new and absence of wear and tear marks.^{25,level III}
 - ◇ No mark in the mouth.^{25,level III}
 - ◇ Frequent breakage.^{25,level III}
- If the compliance is good, check:
 - ◇ Oral hygiene.
 - ◇ Overjet and overbite.
 - ◇ If the crossbite has improved or corrected.
- If the crossbite is not corrected, continue to activate the active components.
- Successful correction of anterior crossbite should be achieved within 6-9 months, If there is no improvement after 9 months, patient should be referred to a specialist for further management.
- The positive overbite is essential to maintain stable result. No retainer is required if positive overbite is achieved.^{26,level III}

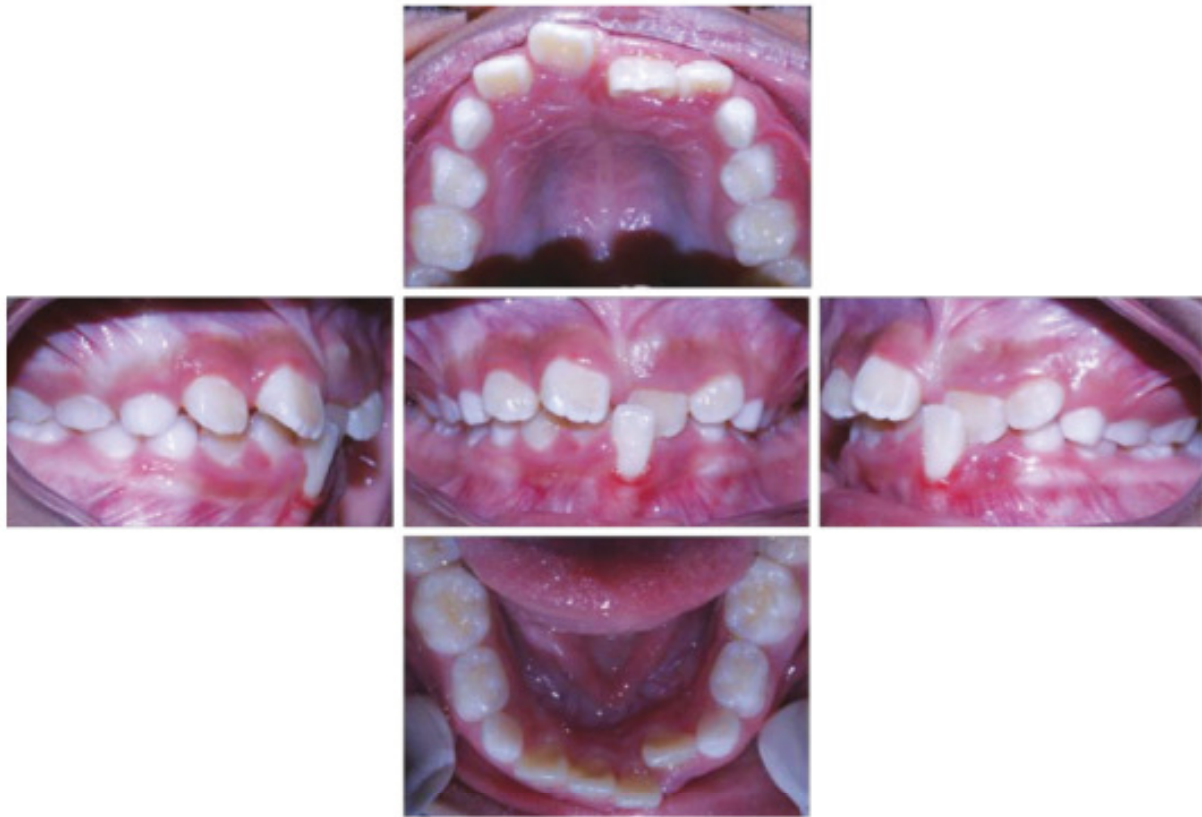

Figure 8a. Pretreatment photos.

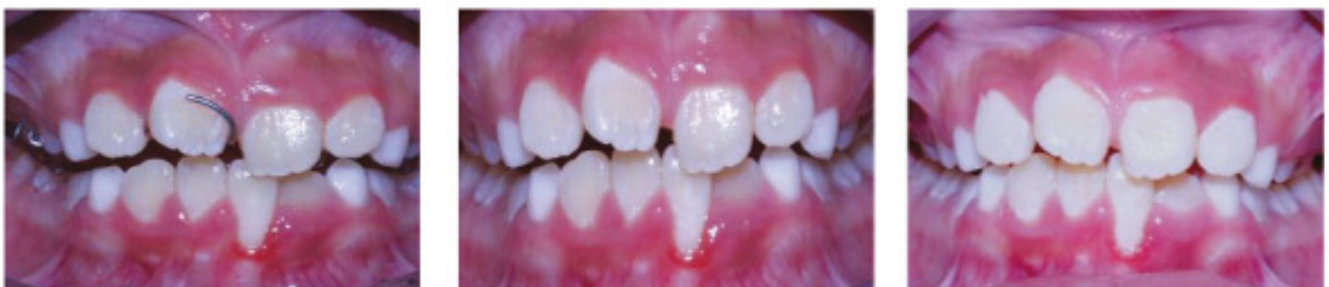

Figure 8b. Mid-treatment photos.

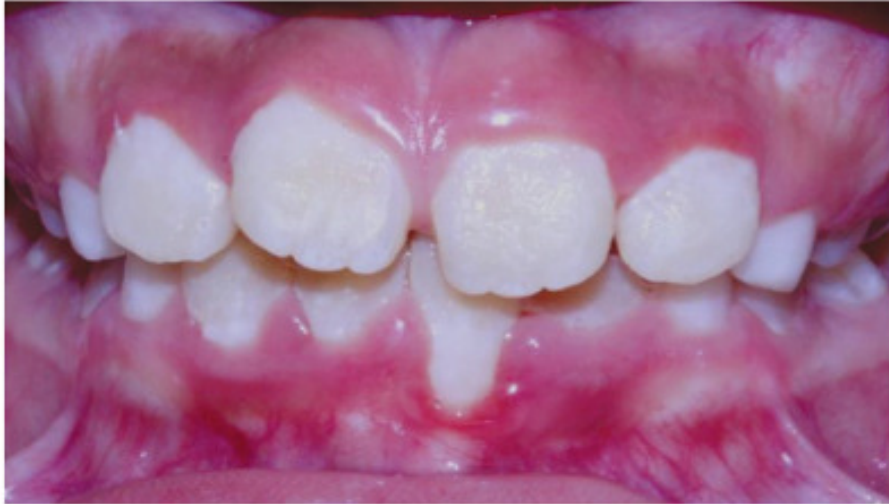

Figure 8c. Post treatment photos : Anterior crossbite crossbite with positive overbite and overjet.

KEY MESSAGE

Referral to specialists if no improvement after 6-9 months.

RECOMMENDATION

No retention is required if there is positive overbite.

(Grade C)

THE FOLLOWING TREATMENT OPTIONS SHOULD BE CARRIED OUT BY THE ORTHODONTIC SPECIALISTS ONLY

11. FIXED APPLIANCE

Most incisors in crossbite are managed with removable appliances if purely tipping movement is required. However, a simple fixed appliance such as the 2 X 4 appliance is preferred when complex movement is needed.^{18,level III;19,level II-2} Fixed appliance is capable of three dimensional tooth movement including bodily movement, root torquing, derotation and movement of multiple teeth.

RECOMMENDATION

Fixed appliance is advocated as the best treatment modality for anterior crossbite.

(Grade A)

12. INCLINED BITE PLANE

Inclined bite plane used to treat anterior crossbite can be fixed or removable. Composite resin has been used as fixed inclined bite plane and is suitable when the anterior crossbite is not more than 1/3 crown length, with no tooth rotation and presence of sufficient space for labial movement. The crossbite should be solely of dental origin.^{27,level III}

13. FUNCTIONAL APPLIANCE

Functional appliance utilizes the forces of the orofacial musculature to move teeth and modify growth to correct a malocclusion. The aim of functional appliance treatment in the correction of anterior crossbite is to stimulate forward maxillary growth and restrain mandibular growth. However, the major effect of functional appliance is mostly dento-alveolar.^{28,level II-2} Function Regulator 3 (FR3), Reverse Twin Block^{29,level III} and Reverse Bionator^{30,level III} appliances have been used in the treatment of anterior crossbite with Class III skeletal base.

14. FACE MASK / PROTRACTION HEADGEAR

The preferred treatment for skeletal maxillary retrusion is anterior movement of the maxilla using a protraction headgear.^{31-33,level III} It has been suggested that for maximum skeletal effect, treatment should commence before the age of 8 years (in early mixed dentition stage).^{31,32,34,level III} In older children, the changes are more likely to be due to dental rather than skeletal. Protraction headgear treatment results in the advancement of maxilla along with a backward and downward rotation of mandible and correction of anterior crossbite.^{35,level III} Associated use of rapid palatal expansion with protraction headgear provides more skeletal effect and less dental change.^{36,level II-2} However, long-term results are dependent on further growth patterns. The direction of force should be slightly below the occlusal plane.

The recommended force is 350-450g per side and the headgear worn at least 12 hours per day.

15. CHIN CUP OR CHIN CAP

Chin cup or chin cap treatment can be used to treat mandibular prognathism in early mixed dentition. This treatment produces a backward rotation of mandible giving the appearance that the mandible has been restrained. The positive changes are lost once treatment is stopped and patient passes through puberty.^{37,level III}

REFERENCES

1. Lin JJ. Differential diagnosis and management of anterior crossbite (II) - definitions. In: Chang Ho-Hua., editor. *Creative Orthodontics Blending the Damon System & TADs to manage difficult malocclusions*. 1. Taipei: Yong Chiem; (2007). pp. 17–26.
2. Moyers RE. *Handbook of orthodontics*, 4th edition. Chicago: Year Book; (1988). p. 410-5.
3. Lin JJ. Prevalence of malocclusion in Chinese children age 9-15. *Clin Dent.Taiwan.*(1985);5:57-65.
4. Rabie AB. Diagnostic criteria for pseudo-Class III malocclusion. *Am J Orthod Dentofacial Orthop.* 2000;117:1–9. doi: 10.1016/S0889-5406(00)70241-1.
5. Mitchell L. *An introduction to Orthodontics*. Oxford University Press. Third Edition (2007) ;Page 140-141.
6. Proffit WR, Fields JR HW, Sarver DM. *Contemporary Orthodontics*. Mosby. Fourth Edition (2000); Page 113-144.
7. Proffit WR. On the aetiology of malocclusion. The Northcroft lecture. *Br J Orthod* 1986; 13:1-11
8. Ngan P, Hu AM, Fields Hw Jr. Treatment of Class III problems begins with differential diagnosis of anterior crossbites. *Pediatr Dent* 1997 sept-oct; 19(6):386-95
9. Long RE, Semb G, Shaw WC. Orthodontic treatment of the patient with complete Cleft of lip, alveolus and palate; Lessons of the past 60 years. *Cleft Palate-Craniofacial Journal* 2000:37;533

10. Harrison JE, Ashby D. Orthodontic treatment for posterior crossbites. *Cochrane Database Syst Rev.*2001;1:CD000979.
11. McNamara JA Jr. Early intervention in the transverse dimension: is it worth the effort? *Am J Orthod Dentofacial Orthop.*2002;121:572-574
12. Thilander B, Lennartsson B. A study of children with unilateral, treated and untreated, in the deciduous dentition-occlusal and skeletal characteristics of significance in predicting the long-term outcome. *J Orofac Orthop.*2002;63:371-383
13. Ramirez G. Treatment of anterior crossbite in the primary dentition with esthetic crowns: Report of 3 cases. *Journal of Pediatric Dentistry* 2011;33:339-42
14. Chow MH. Treatment of anterior crossbite caused by occlusal Interference *Quintessence Int* 1979;10:57-60
15. Croll TP, Riesenberger RE. Anterior crossbite correction in the primary dentition using fixed inclined planes. I. Technique and examples. *Quintessence Int* 1987;18:847-53.
16. Borrie F, Bearn D. Early correction of anterior crossbites: a systematic review. *Journal of Orthodontics* 2011;38:175-184
17. Negi KS, Sharma KR. Treatment of pseudo Class III malocclusion by modified Hawley appliance with inverted labial bow. *J Indian Soc Pedod Prev Dent* 2011;29(1):57-61.
18. Jones JW , O'Neill PD. Anterior crossbite correction and mobile lower central incisors in a 7 year old patient: case report. *Dent Update* 1996; 23:271-74

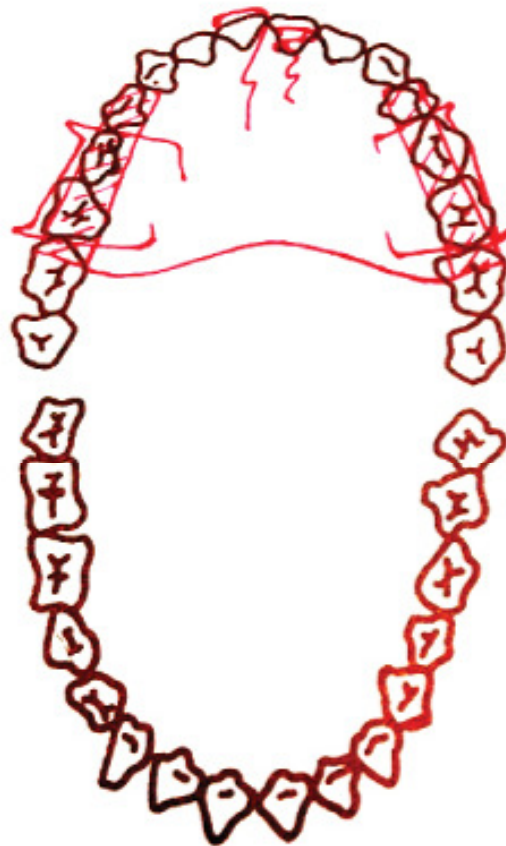19. Thilander B, Rubio G, Pena L, de Mayorga C. Prevalence of temporomandibular dysfunction and its association with malocclusion in children and adolescents: an epidemiologic study related to specific stages of dental development. *Angle Orthodont* 2002;72:146-54
20. Lee BD. Correction of crossbite. *Dent Clin North Am* 1978;22:647-68
21. Sextent T, Croll TP. Anterior Crossbite correction in the primary dentition using reversed stainless steel crowns. *ASDC J Dent Child* 1983; 50:117-20
22. Valentine F, Howitt JW. Implications of early anterior crossbite correction. *ASDC J Dent Child* 1970;37:420-27
23. Clifford FO. Crossbite correction in the deciduous dentition: principles and procedures. *Am J Orthod* 1971;59:343-49
24. Proffit WR, Fields Jr. HW and Sarver DM. *Contemporary Orthodontics* . Fourth Edition, St.Louis, MO (2007); Page 431-443.
25. Mitchell (2007). *An Introduction to Orthodontics*. Chapter17: 178-187
26. Kaplan H. The logic of modern retention procedures. *American Journal of Orthodontics and Dentofacial Orthopaedics* 1988;93:325-340
27. Sari S, Gokalp H, Aras S. Correction of anterior dental crossbite with composite as an inclined plane. *International Journal of Paediatric Dentistry* 2001;11:201-208.
28. Bacceti T, Tollaro E. Sagittal changes after maxillary protraction with expansion in Class III patients in the primary, mixed, and late mixed dentition: a longitudinal retrospective study. *Am J Orthod Dentofacial Orthop* 2000 Jun;117(6):669-80

29. Clark WJ. Twin Block Functional Therapy. Applications in Dentofacial Orthodontics 1995;179-181
30. Giancotti A, Maselli A, Mampieri G, Spano E. Pseudo-Class III malocclusion treatment with Balters' Bionator. Journal of Orthodontics 2003;30:203-215
31. Kajiyama K, Murakami T, Suzuki A. Evaluation of the modified maxillary protractor applied to Class III malocclusion with retruded maxilla in early mixed dentition. Am J Orthod Dentofacial Orthops 2000 Nov;118(5):549-559
32. Saadia M, Torres E. Sagittal changes after maxillary protraction with expansion in Class III patients in the primary, mixed, and late mixed dentitions: a longitudinal retrospective study. Am J Orthod Dentofacial Orthops 2000 Jun;117(6):669-680
33. Gu Y, Rabie AB, Hagg U. Treatment effects of simple fixed appliance and reverse headgear in correction of anterior crossbites. Am J Orthod Dentofacial Orthops 2000 Jun;117(6):691-699
34. Nakamura S, Miyajima K, Nagahara K, Killiany DM, Tsuchiya. Cephalometric changes during self-correction of primary anterior crossbite. ASDC J Dent Child 1999 May-Jun;66(3):175-179
35. Deguchi T, Kanimi R, Ashijawa Y and Rosenstein SW. Very early Face Mask Therapy in Class III children. The Angle Orthodontist 1999;69:349-355

36. Kim JH, Viana MAG, Graber TM, Omerza FF and BeGole EA. The effectiveness of Face Mask Therapy: a Meta-Analysis. *Am J Orthod Dentofacial Orthops* 1999;115:675-685
37. Sugawar J, Asano T, Endo N and Mitani H. Long-term effects of Chincap Therapy on skeletal profile in mandibular prognathism. *Am J Orthod Dentofacial Orthops* 1990;114:492-502

APPENDIX 1

Design of Upper Removable Appliance



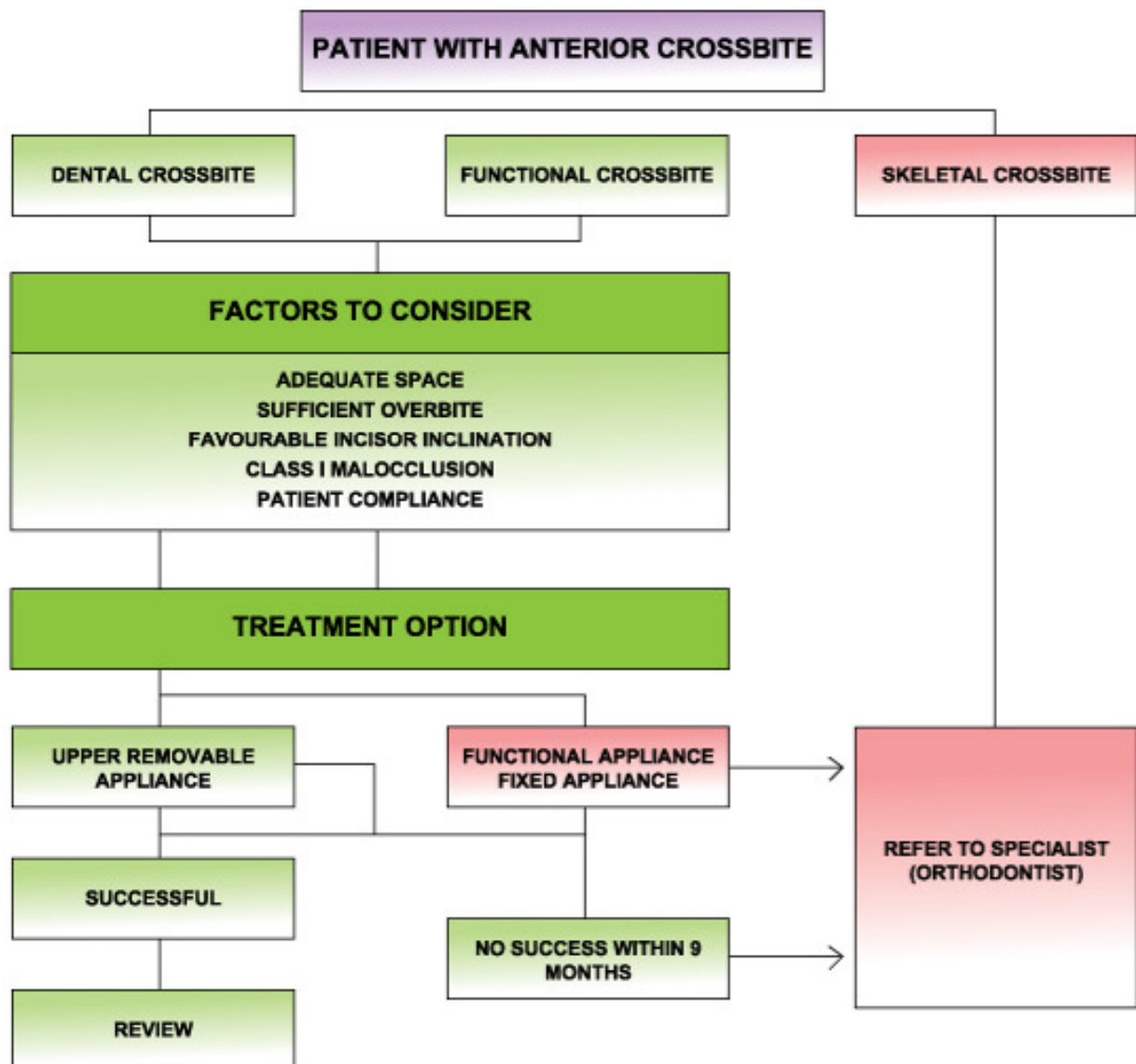
Components	Specifications
Double adam's clasps 16-55,65-26	0.7mm s/s wire
C-clasps 11	0.7mm s/s wire
Z-spring 21	0.5mm s/s wire
Posterior bite plane 54-16,64-26	2-3mm thickness

APPENDIX 2

Instruction for Removable Appliance

1. The appliance should be worn at all times; including meals and in bed at night.
2. The appliance should only be removed during tooth brushing and playing contact sports. It must then be replaced in the mouth at the earliest opportunity.
3. It is very common to feel discomfort, pooling of saliva and altered speech initially, but it should pass in few days once you get used to the appliance.
4. It is important to take care of oral hygiene during the treatment.
5. Avoid hard, sticky and sweet foods.
6. If there is any problem with the appliance, please contact the Orthodontic department as soon as possible. The contact no

Algorithm for Management of Anterior Crossbite in the Mixed Dentition



ACKNOWLEDGEMENTS

The members of the development group of these guidelines would like to express their gratitude and appreciation to the following for their contributions:

- Panel of external reviewers
- Technical Advisory Committee for CPG, Health Technology Assessment Section, Medical Development Division, Ministry of Health, Malaysia for their valuable input and feedback
- All those who have contributed directly or indirectly to the development of the CPG

The clinical photographs contained in these guidelines have been provided by [Dr. Khairil Aznan Mohamed Khan](#), [Dr. Evelyn Lee](#), [Dr. Murshida Marizan Nor](#) and [Dr. Alizae Marny Fadzlin Syed Mohammed](#),

DISCLOSURE STATEMENT

The panel members had completed disclosure forms. None held shares in pharmaceutical firms or acts as consultants to such firms. (Details are available upon request from the CPG Secretariat)

SOURCES OF FUNDING

The development of the CPG on "Management of Anterior Crossbite in the Mixed Dentition" was supported financially in its entirety by the Ministry of Health' Malaysia and was developed without any involvement of the pharmaceutical industry.

